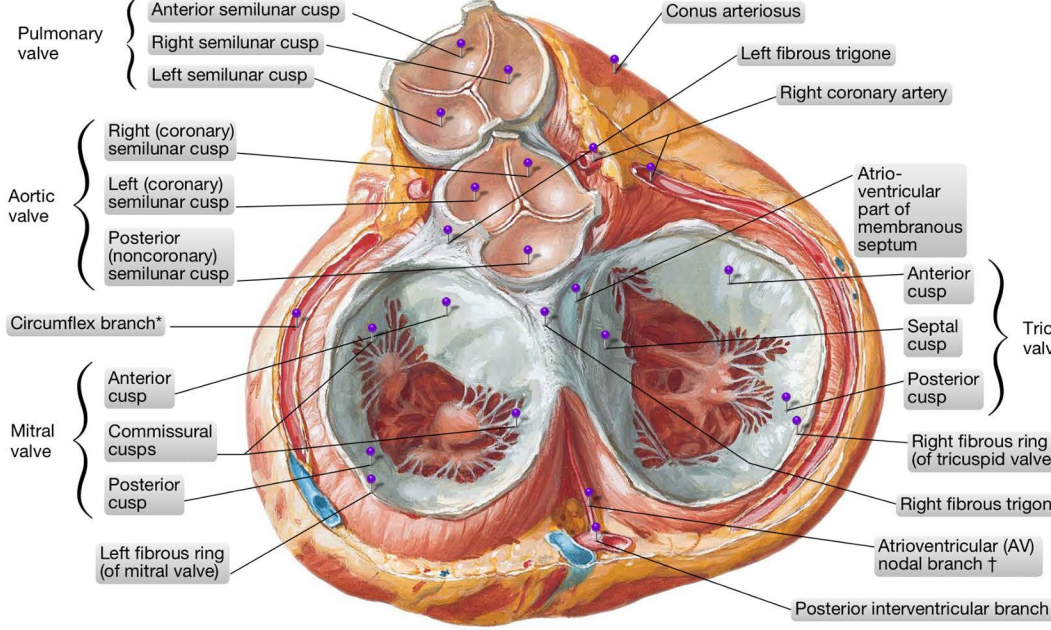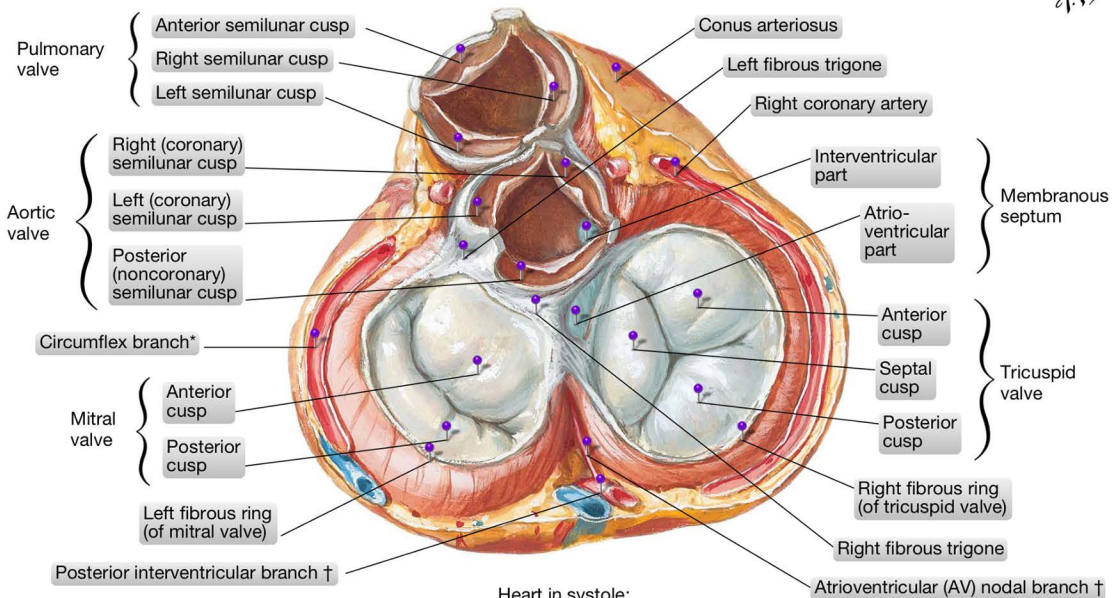


Heart in diastole:
viewed from base with atria removed



Heart in systole:
viewed from base with atria removed

* Of left coronary artery
† Of right coronary artery